


Cold En Bloc Resection of Large Residual Tissue Using the CoinTip™ snare

Parth J. Parekh, M.D.

Therapeutic Intervention in Gastroenterology | Digestive & Liver Disease Specialists and Sentara Norfolk General



Procedure:

En bloc removal of residual tissue by cold snare polypectomy.

Indications:

A patient was returning for a surveillance colonoscopy after a previous endoscopic mucosal resection (EMR) where a large polyp was found.

Treatment:

Upon colonoscopy, a 16mm polyp was found at the previous EMR site. The CoinTip snare was able to grasp the polyp in its entirety and provided an en bloc resection. There was no need for injection or diathermic energy.

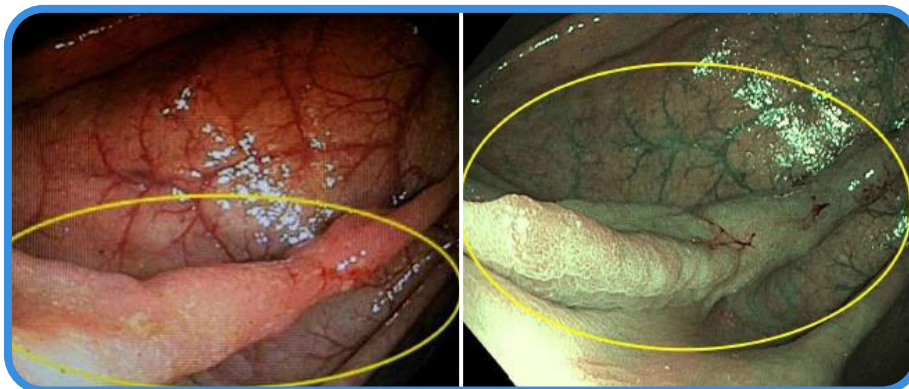


Fig. 1: Residual polyp tissue with and without NBI prior to resection

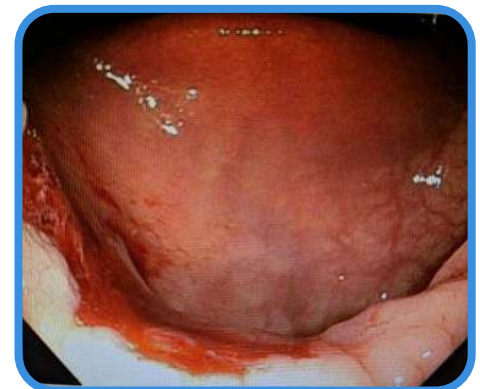

Fig. 2: Clean resection site with the CoinTip snare

Conclusion:

The differentiated design features unique to the CoinTip snare allow for “more control of placement and ease of use, clean cut, and favorable safety profile.”

-DR. PARTH J. PAREKH