

CoinTip™ snare



CoinTip
SNARE



DIAGMED
HEALTHCARE

a STERIS company



STERIS

Endoscopy

The logo for CoinTip SNARE features the word "CoinTip" in a large, bold, blue sans-serif font. Below it, the word "SNARE" is written in a smaller, blue, all-caps sans-serif font. A blue line starts from the left, curves over the top of "CoinTip", and ends in a small, stylized loop that resembles a snare tip.

CoinTip

SNARE

STERIS Endoscopy is continuously innovating to deliver new tools and technologies in the polypectomy and tissue acquisition space.

Our newest addition, the CoinTip snare, is a truly differentiated solution for complex polypectomy procedures including endoscopic mucosal resection (EMR).

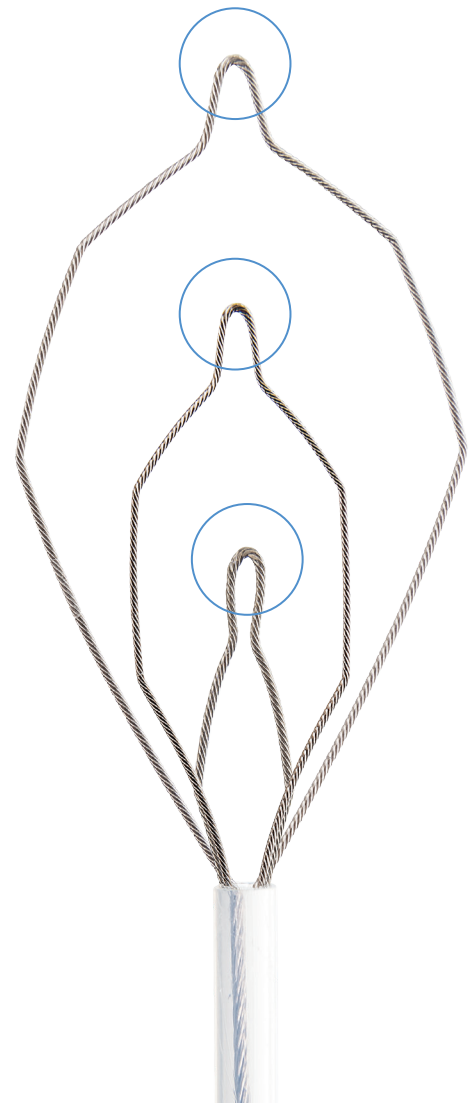

PRODUCT DETAILS:

Not all snares offer the same recruitment, resection, and performance. The innovative CoinTip snare supports hot and cold resection with very unique design features.

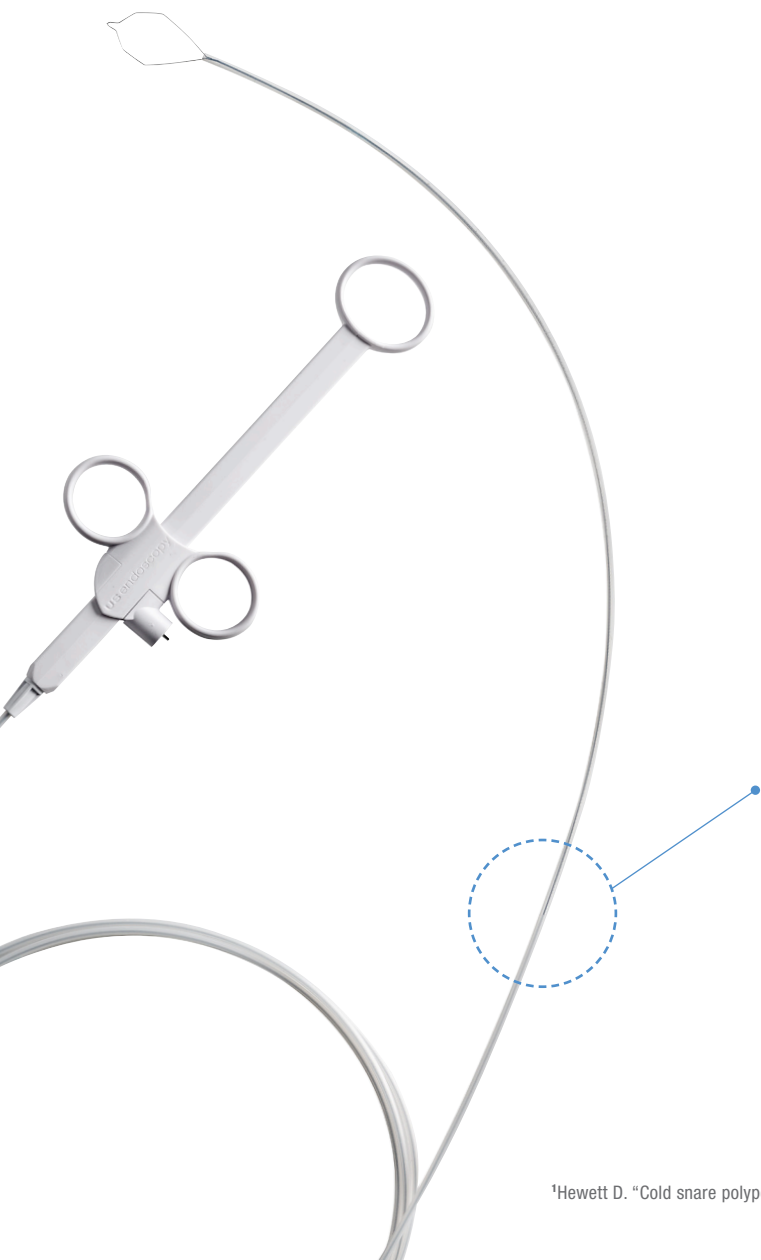
Coined Distal Tip / Snare Loop Wire:

The CoinTip snare leverages the benefits of different wire diameters to support precise hot and cold cutting capabilities.

- Distal tip flattened to 0.010" which is achieved by the manufacturing process of "coining" (*patent pending feature*)
- 0.016" snare loop wire reinforces grip and capture of target tissue
- Snare loop maintains its shape and integrity after multiple resections




¹Din S, Ball A. "Cold snare polypectomy: Does snare type influence outcomes?" Digestive Endoscopy (2015): 1-6.



Double Catheter:

- Catheter includes an internal strain relief for added support during resection to reduce the chance of buckling during resection
- Traditional snare catheters often buckle resulting in incomplete resection¹

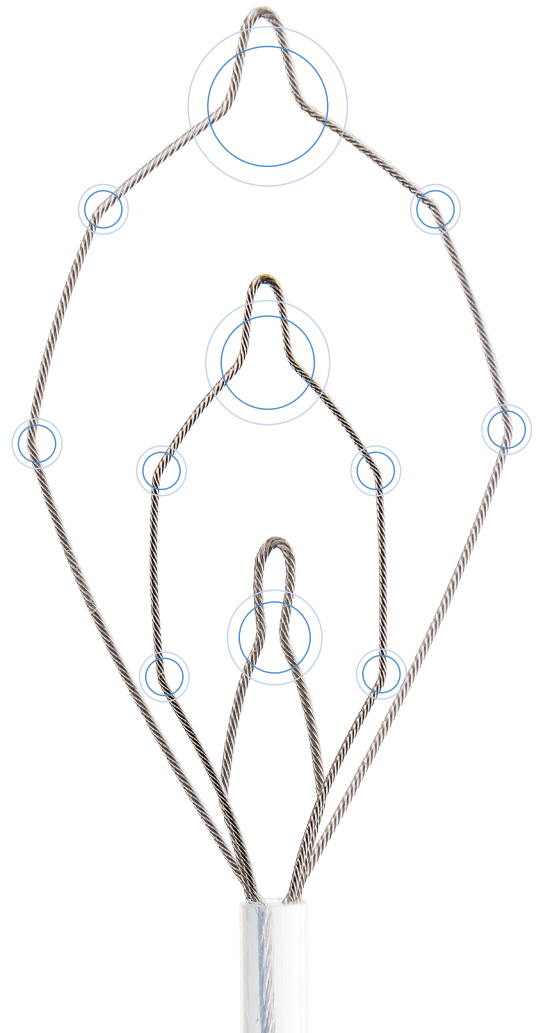


¹Hewett D. "Cold snare polypectomy: optimizing technique and technology." *Gastrointestinal Endoscopy* 82 (2015): 693-696.

Multiple Stages / Memory Points:

The CoinTip snare has dedicated memory points to support EMR and a variety of resection needs, including multiple resections or various types and sizes of polyps.

- **20mm Deltoid Snare** -
ability to encompass majority of lesions with control
- **10mm Hexagonal Snare** -
offers stiffness and precision for additional control
- **6mm Diamond Snare** -
specific placement for diminutive polyps and
cleaning up resection site margins



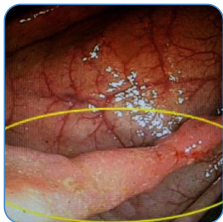CLINICAL CASES:

The following cases highlight the versatility of the CoinTip snare to successfully perform hot and cold resections of challenging lesions, avoid complications such as perforations or delayed bleeding, and utilize its differentiated tip for precise pre-cutting and resection.

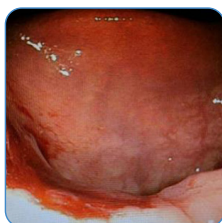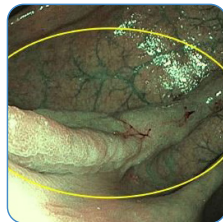
Cold En Bloc Resection of Large Residual Tissue:

Courtesy of Dr. Parth J. Parekh - Therapeutic Intervention in Gastroenterology, Digestive & Liver Disease Specialists and Sentara Norfolk General

Upon colonoscopy, a 16mm polyp was found at the previous EMR site. The CoinTip snare was able to grasp the polyp in its entirety and provided an en bloc resection. There was no need for injection or diathermic energy.



Residual polyp tissue with and without NBI prior to resection



Clean resection site with the CoinTip snare

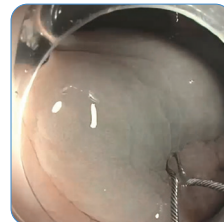


SCAN CODE
for full case details

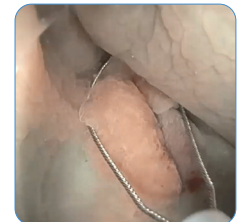Underwater Endoscopic Mucosal Resection:

Courtesy of Dr. David L. Diehl - Geisinger Medical Center

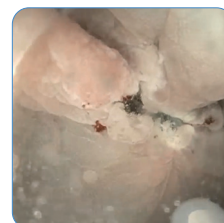Water techniques distend the lumen with water, as opposed to room air or CO₂, which separates the mucosal layers from the muscularis propria so the lesion “floats”.



Polypectomy site flooded with water



Recruitment of the target polyp



Clean resection site following use of CoinTip snare

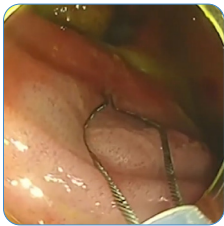


SCAN CODE
to watch this case

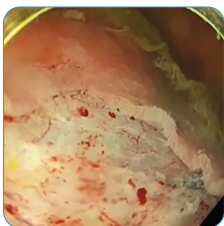
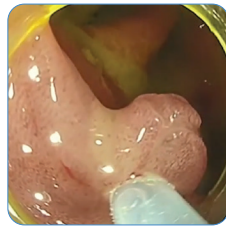
Cold Endoscopic Mucosal Resection:

Courtesy of Professor Bhandari - Queen Alexandra Hospital

Professor Bhandari is able to quickly and easily resect the target lesion en bloc with no polyp fly away.



Recruitment of target lesion



Resection site following cold resection

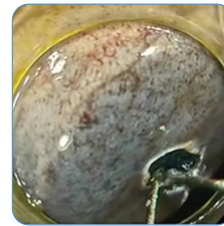


SCAN CODE
to watch this case

Snare Tip Pre-Cut for Cold & Hot Endoscopic Mucosal Resection:

Courtesy of Professor Bhandari - Queen Alexandra Hospital

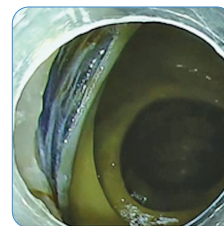
The differentiated tip of the CoinTip snare performs a hot pre-cut to anchor the snare, prior to en bloc cold tissue resection on a challenging lesion located on a fold in the right colon.



Hot pre-cut anchor point to hook snare tip



Capture of target tissue



Complete en bloc resection site on fold



SCAN CODE
to watch this case

ORDERING INFORMATION:

For more information on the CoinTip snare, contact **STERIS Endoscopy** today or visit www.steris.com.

Product Number	Description	Sheath Diameter (mm)	Sheath Length (cm)	Approx. Snare Size (W x L)	Snare Wire Diameter	Units/Box
BX00711110	CoinTip snare	2.5	230	Deltoid Shape: 20 x 32mm Hexagonal Shape: 10 x 27mm Diamond Shape: 6 x 19mm	0.41mm (0.016") Tip: 0.25mm (0.010")	10



a STERIS company

©2021 STERIS Endoscopy. All Rights Reserved.
Unless otherwise indicated, all marks denoted with ® or ™ are registered with the U.S. Patent and Trademark Office, or are trademarks owned by STERIS or its affiliates.

Follow us:    